

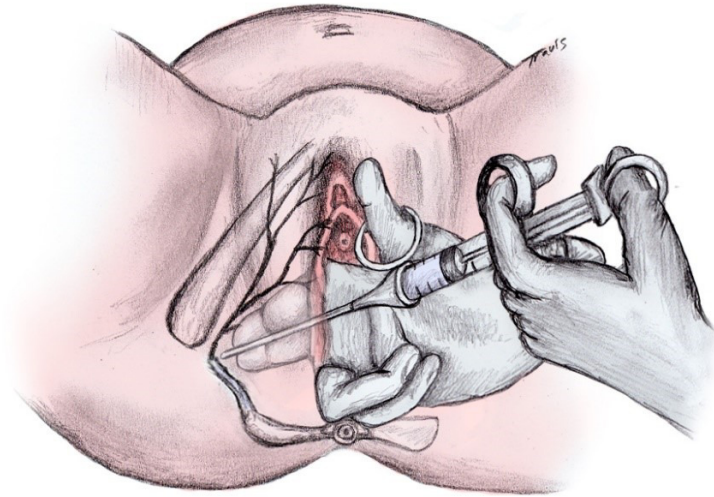Diagram: illustrating perineal infiltration

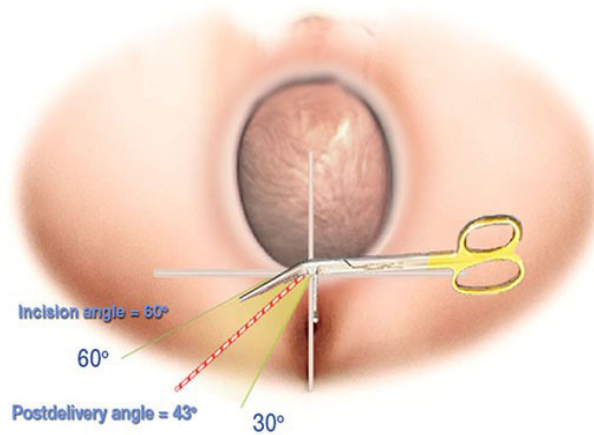


Diagram illustrating correct angle of Right medio-lateral episiotomy